

# Correlation of Some MR Findings in Ankylosing Spondylitis

**Peterová V.<sup>1</sup>, Forejtová Š.<sup>2</sup>, Pavelka K.<sup>2</sup>**

<sup>1</sup>Department of Radiodiagnostics of the First Faculty of Medicine, Charles University in Prague, and General Teaching Hospital, Czech Republic;  
<sup>2</sup>Institute of Rheumatology of the First Faculty of Medicine, Charles University in Prague, Czech Republic.

Received December 19, 2005, Accepted February 23, 2006

**Key words:** Ankylosing spondylitis – MR – Correlation

*The study was supported by grants IGA MZ ČR NK 7732-3 and Research Program Project MZ ČR 00000064165.*

**Mailing Address:** Věra Peterová, MD., PhD., MR, Department of Radiodiagnostics of the First Faculty of Medicine, Charles University, Kateřinská 30, 128 08 Prague, Czech Republic, Phone: +420 224 965 455, e-mail: [vpete30@hotmail.com](mailto:vpete30@hotmail.com)

**Abbreviations and explanations :** ALL – anterior longitudinal ligament; AS – ankylosing spondylitis; BASDAI – Bath Ankylosing Spondylitis Disease Activity Index; BASFI – Bath Ankylosing Spondylitis Functional Index; CRP – C reactive protein; CT – computed tomography; ESR – erythrocyte sedimentation rate; MR – magnetic resonance; PLL – posterior longitudinal ligament; SpA – the seronegative spondyloarthritides; STIR – short T1 inversion recovery; T1WI – T1 weighted images; T2WI – T2 weighted images.

**Abstract:** Results of the spinal magnetic resonance (MR) in patients with ankylosing spondylitis (AS) were evaluated prospectively in correlation with age, symptoms duration and some inflammatory tests. 20 patients with AS were prospectively examined by complex clinical and laboratory tests. All were examined with X-ray and 1,5T magnetic resonance. The visibility, margination and extent of acute and chronic pathological vertebral lesions were qualitatively and quantitatively compared statistically. The axial form of AS strongly prevailed (70%). If acute AS vertebral changes are evaluated CRP did not correlated with local vertebral changes, erythrocyte sedimentation rate and functional tests BASDAI and BASFI correlated with vertebral changes on the various significance level due to the MR sequence used. Chronic spinal changes correlated with age of the patients and duration of the symptoms. BASFI test with chronic changes did not correlate. MR is the best method for evaluating changes in vertebrae and in the adjacent soft tissues. The excellent evaluation of acute and chronic local MR changes of vertebral marrow is provided by Braun's scoring system. In acute AS changes short T1 inversion recovery (STIR) sequence showed most vertebral marrow changes, while in the chronic AS changes T1 weighted images were the statistically significantly best sequence in depicting the marrow and ligamentous pathology.

---

### **Introduction**

Ankylosing spondylitis (AS) is a systemic inflammatory affection of locomotive organ which belongs to the seronegative spondyloarthritides (SpA). The disease affects mostly the axial skeleton, predominantly the spinal ligaments, further sacroiliac, costovertebral and sternocostal articulations. Entezitis in the ligamentous insertion spot represents the primary affection in AS. It leads to the formation of erosions, with consecutive fibrosis and production of the new bone. Inflammatory process in ventral and lateral edges of vertebral bodies leads to the ossification of peripheral parts of tendinous annulus of cartilage and surrounding ligaments. Shoulders and hips are simultaneously affected in rhizomelic form (about 35% of patients), peripheral joints are affected in peripheral form (about 20% of patients) [1]. According to the previous data prevalence of AS reached to 0.05% of inhabitants, but recent studies demonstrated that the occurrence of this disease varies about 0.2–0.3% [2–5]. Sporadic atypical forms can appear in up to 1% of population. The disease starts usually in 2<sup>nd</sup> or 3<sup>rd</sup> decade, the accession of the disease after the age of 40 is unusual. Fully developed disease manifestation occurs predominantly among males (ratio males: females is 7:10) [1–5]. Inflammatory back pain, reduction of spinal movements in all planes and spinal deformities belong to the characteristic clinical findings. Besides the spinal affection disease can often have the extraspinal manifestation, i.e. affection of eyes, skin, mucous membranes, cardiac conduction disturbances, aortic regurgitation, apical pulmonary fibrosis,

renal affections, cauda equina syndrome etc. The occurrence of the disease is strongly associated with the presence of the antigen HLA B-27, which occurs in AS in 95% [6].

### Patients and methods

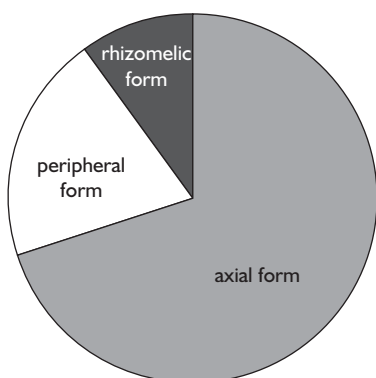
The studied group of patient consisted of 20 patients, 17 males and 3 females in the age from 20 to 80 years (average age of  $40.14 \pm 13.68$  years). We further investigated the group of age and sex matched healthy controls (average age of 41.25 years). All patients were prospectively followed clinically (by rheumatologist and neurologist), by X-ray of the whole spine and MR during years 2003 and 2005. Axial form of the disease was present in 14 patients (70%), peripheral form in 4 (20%) and rhizomelic form in 2 (10%). Five AS patients (25%) were in the 2<sup>nd</sup> stage of the disease, three (15%) in the 3<sup>rd</sup>, nine (45%) in the 4<sup>th</sup> and three (15%) in the 5<sup>th</sup> stage of the disease. Activity of the disease was evaluated by functional indexes: the Bath Ankylosing Spondylitis Disease Activity Index (BASDAI) [7] and the Bath Ankylosing Spondylitis Functional Index (BASFI) [8] indexes. The complaints of the patients brought along AS lasted  $13.70 \pm 9.36$  years. The duration of the disease from the correct diagnosis assessment was in average  $4.16 \pm 4.62$  years.

1.5 T MR was done at Philips device in the range thoracic and lumbar regions in 3 mm sagittal and transversal planes parallel with intervertebral discs using sequences spin echo (SE) in T1 weighted images (T1WI), turbo spin echo (TSE) in T2 weighted images (T2WI) and short T1 inversion recovery (STIR) without using contrast material. In transversal planes in T2WI matrix  $512 \times 512$  was used, in all other planes and sequences matrix  $256 \times 256$  was used. The findings were evaluated by a visual way from the PC monitor. On transversal MR images the total width of the spinal canal and the width of anterior and posterior longitudinal ligaments and that of yellow ligament were measured (ALL, PLL and FL). The visibility, margination and extent bone marrow of all vertebral bodies, all imaged discs and ligaments were evaluated by an experienced musculoskeletal radiologist. Acute and chronic changes according to Braun's scoring system [9, 10, 11] were evaluated twice by standard indexes and average value was made from those measurements. Healthy controls without clinical signs of vertebral affection were examined by MR and laboratory tests only. Both acute and chronic MR findings in all AS patients were statistically correlated with erythrocyte sedimentation rates (ESR), C reactive proteins values (CRP), age of the patients, duration of the disease, duration of the patient complaints, and results of BASDAI and BASFI tests. Standard statistical calculations were counted in table processor Excel. The correlations were identified by Student's paired T test. Minimal measurable deviation (standard deviation – SDD) between two results of radiologist in particular patient was counted with mathematical statistics procedures.

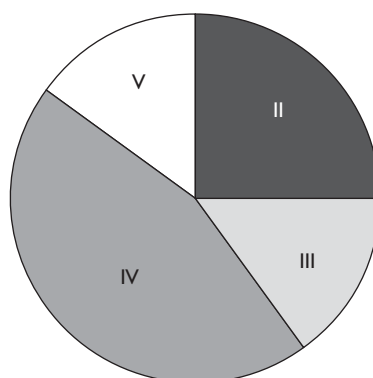
## Results

The cohort of our AS patients included 20 patients with strong prevalence of males. The representation of the particular forms of the disease is shown at the Graph 1. The axial form of the disease strongly prevailed (70%) in our patients group. The disease stage is demonstrated at Graph 2. From that graph it is obvious, that the stage 4 was in our patients group the most frequent (45%). Results of the main auxiliary laboratory tests (aimed to inflammation), of additional clinical tests and timing of some symptoms of the patients are depicted in Table 1. The average value of erythrocyte sedimentation rate (ESR) was  $31.60 \pm 25.05$ . The average value of C reactive protein (CRP) in AS patients was  $19.83 \pm 23.68$ .

Average BASDAI level was in AS patients  $4.08 \pm 1.75$  and that of BASFI was  $5.06 \pm 2.05$ . These scores are quite high and represent more severe functional affection, since in perfectly healthy individuals are their levels around zero. In



Graph 1 – The representation of the particular forms of disease in our cohort of AS patients: axial form = 14 patients (70%), peripheral form = 4 patients (20%), rhizomelic form = 2 patients (10%).



Graph 2 – The stages of ankylosing spondylitis in our cohort of AS patients: II<sup>d</sup> stage = 5 patients (25%), III<sup>d</sup> stage = 3 patients (15%), IV<sup>th</sup> stage = 9 patients (45%), V<sup>th</sup> stage = 3 patients (15%).

**Table 1 – Some additional investigational data in the cohort of AS patients (n = 20 patients)**

Total duration of the patients symptoms	$13.70 \pm 9.36$
Duration of the symptoms from the real diagnosis establishment	$4.16 \pm 4.62$
ESR	$31.60 \pm 25.05$
CRP	$19.83 \pm 23.68$
BASDAI	$4.08 \pm 1.75$
BASFI	$5.06 \pm 2.05$

Explanations: AS – ankylosing spondylitis, ESR – erythrocyte sedimentation rate, CRP – C reactive protein, BASDAI – the Bath Ankylosing Spondylitis Disease Activity Index, BASF – the Bath Ankylosing Spondylitis Functional Index

Tables 2 and 3 the results of acute and chronic vertebral changes are shown. The data of real values of both measurements of T1WI, T2WI and STIR, their average values together with differences between both measurements and their standard deviations are introduced at Table 2. Results of chronic vertebral changes together with differentiation between both basic values and their standard deviation are depicted at Table 3. The acute vertebral changes were best depicted in STIR sequence, in comparison with T2WI even though the differences were not significant. T1WI had in this discrimination the worst results for acute changes,

**Table 2 – MR results of acute vertebral marrow and discal changes in the cohort of AS patients obtained by double measurement; their average values, differences and standard deviations (n = 20 patients)**

	1 <sup>st</sup> measurement	2 <sup>nd</sup> measurement	average	difference	SDD
T1WI	12.70	12.40	12.55	0.30	1.59
T2WI	11.55	10.95	11.25	0.60	1.20
STIR	14.25	13.90	14.08	0.35	2.66

Explanations: MRI – magnetic resonance imaging, AS – ankylosing spondylitis, T1WI – T1 weighted images, T2WI – T2 weighted images, STIR – short T1 inversion recovery, SDD – standard deviation

**Table 3 –MR results of chronic vertebral marrow and discal changes in the cohort of AS patients obtained by double measurement; their average values, differences and standard deviations (n = 20 patients)**

	1 <sup>st</sup> measurement	2 <sup>nd</sup> measurement	average	difference	SDD
T1WI	25.65	25.55	25.60	0.10	0.20
T2WI	22.20	22.20	22.20	0.00	1.05
STIR	17.20	16.45	16.83	0.75	3.78

Explanations: MRI – magnetic resonance, AS – ankylosing spondylitis, T1WI – T1 weighted images, T2WI – T2 weighted images, STIR – short T1 inversion recovery, SDD – standard deviation

**Table 4 – Correlation of acute MR vertebral and discal changes with some inflammatory and functional parameters in the cohort of AS patients (n = 20 patients)**

	ESR, p <	CRP, p <	BASDAI, p <	BASFI, p <
T1WI	0.005	NS	0.001	0.005
T2WI	0.005	NS	0.005	0.01
STIR	0.01	NS	0.001	0.001

Explanations: MRI – magnetic resonance imaging, AS – ankylosing spondylitis, T1WI – T1 weighted images, T2WI – T2 weighted images, ESR – erythrocyte sedimentation rate, CRP – C reactive protein, BASDAI – the Bath Ankylosing Spondylitis Disease Activity Index, BASFI – the Bath Ankylosing Spondylitis Functional Index, NS – non-significant

**Table 5 – Correlation of chronic MR vertebral and discal changes in the cohort of AS patients (n = 20 patients) with their age, duration of symptoms and functional index BASFI**

	Age, p <	Total duration of patients symptoms, p <	Duration from the diagnosis establishment, p <	BASFI p <
T1WI	0.005	0.01	0.01	NS
T2WI	0.01	0.05	0.01	NS
STIR	0.01	0.01	0.01	NS

Explanations: MRI – magnetic resonance imaging, AS – ankylosing spondylitis, T1WI – T1 weighted images, T2WI – T2 weighted images, ESR – erythrocyte sedimentation rate, CRP – C reactive protein, BASDAI – the Bath Ankylosing Spondylitis Disease Activity Index, BASFI – the Bath Ankylosing Spondylitis Functional Index, NS – non-significant

**Table 6 – Correlation of acute and chronic MRI vertebral and discal changes in the cohort of AS patients (n = 20 patients) with ratios of particular MR sequences**

Ratio	Acute changes, p <	Chronic changes, p <
STIR/T2WI	NS	0.05
STIR/T1WI	NS	0.01
T2WI/T1WI	NS	NS

Explanations: MRI – magnetic resonance imaging, AS – ankylosing spondylitis, T1WI – T1 weighted images, T2WI – T2 weighted images, NS – non-significant

**Table 7 – MR evaluation of acute and chronic discovertebral changes**

AS MR Evaluation of Acute Affection

- 0 = normal, no lesions
- 1 = mild enhancement and bone marrow edema covering < 25% VU
- 2 = moderate bone marrow edema covering < 50% VU
- 3 = severe bone marrow edema covering > 50% VU
- 4 = bone marrow edema and erosion covering < 25%
- 5 = bone marrow edema and erosion covering < 50% VU
- 6 = bone marrow edema and erosion covering > 50% VU

AS MR Evaluation of Chronic Affection

- 0 = normal, no lesions
- 1 = minor sclerosis/suspicion of relevant changes
- 2 = sclerosis/vertebral squaring/ton shaped vertebrae/ possible syndesmophyte
- 3 = one or two syndesmophytes/minor erosion
- 4 = more than two syndesmophytes/severe erosions
- 5 = vertebral bridging
- 6 = vertebral fusion

Explanations: AS – ankylosing spondylitis, MR – magnetic resonance imaging, VU – vertebral unit (disc with halves of neighbouring vertebrae)

though if compared with STIR and T2WI the differences were not significant. The chronic vertebral changes were significantly best shown in T1WI and STIR was the worst sequence in depicting them. Some correlation of acute vertebral changes is shown in Table 4. Those statistical correlations in acute vertebral changes showed that CRP did not correlate with local vertebral changes; on the other hand ESR

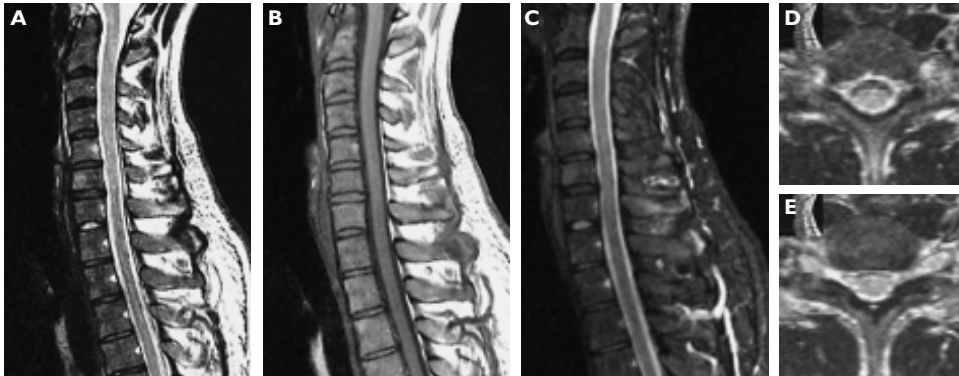


Figure 1 – P. Z. 26year old AS patient, MR of C/Th spine, a) T2 weighted image of TSE mode, b) T1 weighted image of SE mode, c) T2 weighted image of STIR mode, sagittal slices; d, e) T2 weighted image of TSE mode, transversal slices, segm. C6/7. Flattening of physiological spinal curvature. Hypertrophy of ALL in the range of C7 – Th5, depicted in detail on sagittal slices. Focal remodelling of vertebral marrow C6 in the ventral region and that of C5 in the dorsal region (entezitis), chondrosis of C6/7 and C7/Th1 with relative spacious spinal canal.

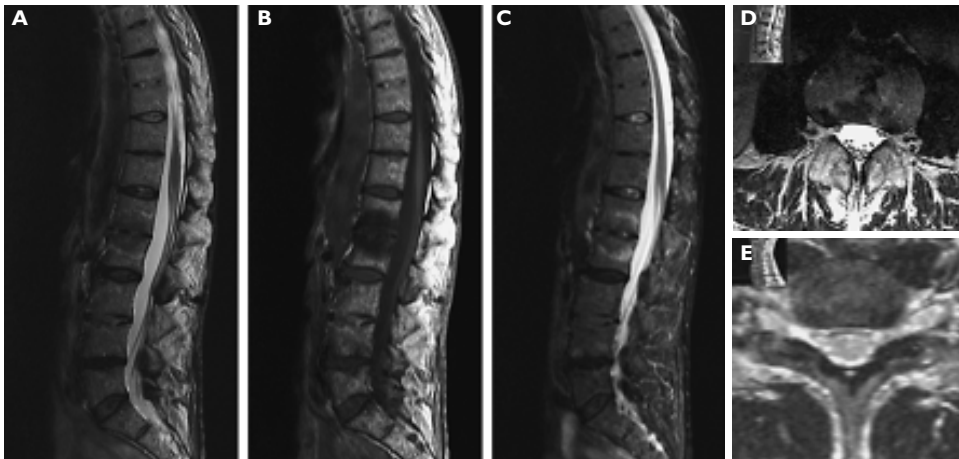


Figure 2 – J. S. 62year old AS patient, MR of ThL spine, a) T2 weighted image of TSE mode, b) T1 weighted image of SE mode, c) T2 weighted image of STIR mode, sagittal slices; d, e) T2 weighted images of TSE mode, transversal slices, segm. L3/4 and L1/2. Focal signal change in vertebral end plates of L1,L2,L3 and L4 (mixed signal in T2 weighted images and hyposignal in T1 weighted images with hypersignal margin in STIR) with destruction of disc L1/2 (Andersson lesion). Square shape of thoracic vertebrae. Chondrosis of Th7/8, Th9/10 and L3/4 with their partial damage. Chondrosis of Th11/12 and L4/5 (bulging) with end plates erosions in relative spacious spinal canal.

and BASDAI or BASFI tests correlated the vertebral changes on the various significance levels due to the MR sequence used. From the table results that T2WI and STIR is better in correlation with BASDAI or BASFI tests in comparison with T1WI sequence if acute vertebral changes are taken into consideration.

Correlation of chronic vertebral changes with age, duration of the disease and BASFI are shown in Table 5. The correlation was significant with age, the duration of the symptoms of AS and with the duration of the diagnosis of AS, while the correlation with BASFI test was not statistically significant.

Table 6 shows that when acute spinal changes were evaluated, differences between particular sequences in each patient were not significantly different. When results of chronic spinal changes obtained by sequences STIR and T2WI were evaluated, they differed significantly; the same was found for STIR and T1WI, while the difference between T1WI and T2WI was not significant.

Acute and chronic spinal changes according to Braun's scoring system were evaluated in 12 segments (from Th6/7 to L5/S1) in each patient. Table 7 depicts the scoring system.

## Discussion

X-ray found that sacroiliitis is obligatory presents and represents the crucial manifestation of the disease in the diagnostics. New bone formation in the peripheral fascicles of the discal tendineous ring (syndesmophytes) is pathognomonic for AS in spinal region. Discitis (i.e. Andersson's lesion) represent the most common spinal complication. Discitis can be either inflammatory or non-inflammatory. Inflammatory changes on spinal X-rays represent the circumscribed defect of the vertebral body, rimmed by marked sclerotization with characteristic reduction of the disc. Non-inflammatory diskitis rises on the strength of fatigue fracture in the porotic terrain and affects predominantly cervical and thoracic spine. Discs are not narrowed, vertebral bodies are fragmented, their shift can appear [12, 13]. Hypertrophy, calcification or even ossification of the posterior longitudinal ligament (PLL) can be in AS patients the cause of cervical myelopathy. The most appropriate examination method for AS appears to be the magnetic resonance (MR). Using the Braun's scoring system [9, 10, 11] this method enables to evaluate the so called activity index and index of chronicity of inflammatory changes in the sacroiliac joints and spine.

For the demonstration of bone cortex, bone marrow changes and periosteal change T1 and T2WI SE sequences the magnetic resonance is the best method [14, 15, 16]. However, for calcified tissues, plain radiographs and spiral CT, MR combination are better. Conspicuity for the vertebral marrow changes is higher (73.3%) and the margins more definite (68.8%) on T1WI of SE than on T2WI TSE sequences. Marrow fat has high signal intensity in both T1 and T2WI, masking all high-signal bone lesions. STIR, designed to suppress signal from fat, also enhances the signal from tissue with long T1 and T2 relaxation times, such as inflammatory



tissue. Motion artefacts are most severe on the STIR and least severe on the T1WI SE images. The T2WI TSE and STIR sequences are superior to the non-contrast or even contrast-enhanced T1WI SE sequence for depicting musculoskeletal lesions [16, 17]. Quantitative measurements indicate that lesions are more noticeable on STIR images than on T1WI, but this difference is not significant. Factors related to image quality, including reduction in motion artefacts and image uniformity, are generally superior on T1WI. T1WI, T2WI and STIR sequences all provide a high degree of sensitivity for depiction of most types of bone marrow abnormalities. The combination of T1WI and STIR images is highly effective for the evaluation of all bone marrow lesions. STIR even appears to be superior in the following situations: investigation of the cervical vertebrae, early detection of periduritis and lesions of the posterior arch [18, 19, 20]. STIR appears especially useful for the evaluation of spinal red marrow, where contrast between normal and infiltrated marrow is greater than with either gradient-echo or T1WI. STIR is also extremely sensitive for evaluation of osteomyelitis, including soft tissue extent. In more peripheral (yellow) marrow, T1WI are usually as sensitive as STIR. Limitations of STIR include artefacts, in particular motion artefact that at high field strength necessitates motion compensation. Because of extreme sensitivity to water content, STIR may overstate the margins of a marrow lesion [21, 22, 23]. The bone marrow edema pattern zone is ill-defined and hyperintense on STIR, hyperintense on T2WI and hypointense on T1WI and it could consist of several abnormalities (bone marrow necrosis, abnormal trabeculae, bone marrow fibrosis or edema) or it even could be composed of normal tissue (mostly fatty marrow with intact trabeculae and blood vessels).

In our study we found, in agreement with recent data of other authors [9, 10], that the acute changes of vertebral marrow due to Braun's score were best depicted in STIR sequence, on the second place was T2WI. The artefacts were there minimal. T1WI had in this discrimination the worst results. The chronic changes of vertebral marrow due to Braun's score were significantly best shown in T1WI and further in T2WI. STIR was the worst sequence in depicting them.

Why CRP levels in our patients did not correlate with local vertebral changes is hard to explain, maybe the group of patients was small and more patients has to be investigated to explain that particular result. ESR and BASDAI or BASFI tests correlated, as we supposed, with the vertebral changes on the various significance levels according to the choice of used MR sequences.

## Conclusion

MR was the best method for evaluation changes in vertebrae and adjacent soft tissues. In acute AS changes short T1 inversion recovery (STIR) sequence showed most vertebral marrow changes, while in the chronic AS changes T1 weighted images were the statistically significantly best sequence in depicting the marrow and ligamentous pathology.

## References

1. BOSTAN E. E., BORMAN P., BODUR H.: Functional disability and quality of life in patients with ankylosing spondylitis. *Rheumatol. Int.* 23: 121–126, 2003.
2. BRAUN J., BOLLOU M., REMLINGER G., EGGENS U., RUDWALEIT M., DISTLER A., SIEPER J.: Prevalence of spondylarthropathies in HLA-B27 positive and negative blood donors. *Arthritis Rheum.* 41: 58–67, 1998.
3. MOLL J. M., WRIGHT V.: New York clinical criteria for ankylosing spondylitis: a statistical evaluation. *Ann. Rheum. Dis.* 32: 354–363, 1973.
4. TRONTZAS P., ANDRIANAKOS A., MIYAKIS S., PANTELIDOU K., VAFIADOU E., GARANTZIOTOU V., VOUDOURIS C.: Seronegative spondyloarthropathies in Greece: a population-based study of prevalence, clinical pattern, and management. The ESORDIG study. *Clin. Rheumatol.* 24: 583–589, 2005.
5. SARAUX A., GUILLEMIN F., GUGGENBUHL P., ROUX C. H., FARDELLONE P., LE-BIHAN E., CANTAGREL A., VALCKENAERE I., EULLER-ZIEGLER L., FLIPO R. M., JUVIN R., BEHIER J. M., FAUTREL B., MASSON C., COSTE J.: Prevalence of spondylarthropathies in France – 2001. *Ann. Rheum. Dis.* 64: 431–435, 2005.
6. BOWNESS P., ZACCAI N., BIRD L., JONES E. Y.: HLA – B27 and disease pathogenesis: new structural and functional insights. *Expert. Rev. Mol. Med.* 26: 1–10, 1999.
7. GARRETT S., JENKINSON T., KENNEDY L. G., WHITELOCK H., GAISFORD P., CALIN A.: A new approach to defining disease status in ankylosing spondylitis: the Bath Ankylosing Spondylitis Disease Activity Index. *J. Rheumatol.* 21: 2286–2291, 1994.
8. CALIN A., GARRETT S., WHITELOCK H., KENNEDY L. G., O’HEA J., MALLORIE P., JENKINSON T.: A new approach to defining functional ability in ankylosing spondylitis: The development of the Bath Ankylosing Spondylitis Functional Index. *J. Rheumatol.* 21: 2281–2285, 1994.
9. BARALIAKOS X., LANDEWÉ R., HERMANN K. G., LISTING J., GOLDER W., BRANDT J., RUDWALEIT M., BOLLOU M., SIEPER J., VAN DER HEIJDE D., BRAUN J.: Inflammation in ankylosing spondylitis: a systematic description of the extent and frequency of acute spinal changes using magnetic resonance imaging. *Ann. Rheum. Dis.* 64: 730–734, 2005.
10. BRAUN J., BARALIAKOS X., GOLDER W., HERMANN K. G., LISTING J., BRANDT J., RUDWALEIT M., ZUEHLSDORF S., BOLLOU M., SIEPER J., VAN DER HEIJDE D.: Analysing chronic spinal changes in ankylosing spondylitis: a systematic comparison of conventional X rays with magnetic resonance imaging using established and new scoring systems. *Ann. Rheum. Dis.* 63: 1046–1055, 2004.
11. BRAUN J.: Imaging and scoring in ankylosing spondylitis. *Best Practise & Research Clinical Rheumatology* 16: 573–604, 2002.
12. CAWLEY M. I. D., CHALMERS T. M., KELLEGREN J. H., BALL J.: Destructive lesions of vertebral bodies in ankylosing spondylitis. *Ann. Rheum. Dis.* 31: 345–358, 1972.
13. LEVINE D. S., FORBAT S. M., SAIFUDDIN A.: MRI of the axial skeletal manifestations of ankylosing spondylitis. *Clin. Radiol.* 59: 400–413, 2004.
14. PLECHA D. M.: Imaging of bone marrow disease in the spine. *Semin. Musculoskelet. Radiol.* 4: 321–327, 2000.
15. PUI M. H., GOH P. S., CHOO H. F., FOK E. C.: Magnetic resonance imaging of musculoskeletal lesions: comparison of three fat-saturation pulse sequences. *Australas Radiol.* 41: 99–102, 1997.
16. SCHMID M. R., HODLER J., VIENNE P., BINKERT C. A., ZANETTI M.: Bone marrow abnormalities of foot and ankle: STIR versus T1-weighted contrast-enhanced fat-suppressed spin-echo MR imaging. *Radiology* 224: 463–469, 2002.
17. VANEL D., DROMAIN C., TARDIVON A.: MRI of bone marrow disorders. *Eur. Radiol.* 10: 224–229, 2000.

18. COVA M., FREZZA F., CHALKIAS S., UKMAR M., POZZI MUCELLI R.: Comparative evaluation of the SPIR sequence with gadolinium and other sequences in bone diseases. *Radiol. Med. (Torino)* 85: 370–377, 1993.
19. HAYASHI H., OKADA K., HASHIMOTO J., TADA K., UENO R.: Cervical spondylotic myelopathy in the aged patient. A radiographic evaluation of the aging changes in the cervical spine and etiologic factors of myelopathy. *Spine* 13: 618–625, 1988.
20. HILFIKER P., ZANETTI M., DEBATIN J. F., MCKINNON G., HODLER J.: Fast spin-echo inversion-recovery imaging versus fast T2-weighted spin-echo imaging in bone marrow abnormalities. *Invest. Radiol.* 30: 110–114, 1995.
21. HITTMAIR K., TRATTNIG S., HEROLD C. J., BREITENSEHER M., KRAMER J.: Comparison between conventional and fast spin-echo stir sequences. *Acta Radiol.* 37: 943–949, 1996.
22. JONES K. M., UNGER E. C., GRANSTROM P., SEEGER J. F., CARMODY R. F., YOSHINO M.: Bone marrow imaging using STIR at 0.5 and 1.5 T. *Magn. Reson. Imaging* 10: 169–176, 1992.
23. NAKATSU M., HATABU H., ITOH H., MORIKAWA K., MIKI Y., KASAGI K., SHIMONO T., SHOJI K., SHIMADA Y., IMAMURA M., KONISHI J.: Comparison of short inversion time inversion recovery (STIR) and fat-saturated (chemsat) techniques for background fat intensity suppression in cervical and thoracic MR imaging. *J. Magn. Reson. Imaging* 11: 56–60, 2000.